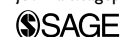

Rapid Central Vein Assessment (RaCeVA): A systematic, standardized approach for ultrasound assessment before central venous catheterization

The Journal of Vascular Access
2019, Vol. 20(3) 239–249
© The Author(s) 2018
Article reuse guidelines:
sagepub.com/journals-permissions
DOI: 10.1177/1129729818804718
journals.sagepub.com/home/jva



Timothy R Spencer¹ and Mauro Pittiruti²

Abstract

Ultrasound technology has revolutionized the practice of safer vascular access, for both venous and arterial cannulation. The ability to visualize underlying structures of the chest, neck, and upper/lower extremities provides for greater success, speed, and safety with all vascular access procedures. Ultrasound not only yields superior procedural advantages but also provides a platform to perform a thorough assessment of the vascular structures to evaluate vessel health, viability, size, and patency, including the location of other important and best avoided anatomical structures—prior to performing any procedures. Such assessment is best performed using a systematic and standardized approach, as the Rapid Central Vein Assessment, described in this study.

Keywords

Ultrasound, assessment, central venous access, patient safety, outcomes, standardized

Date received: 5 June 2018; accepted: 26 June 2018

Introduction

There is clear evidence that ultrasound (US) offers significant advantages in patient safety and procedural quality during the placement of central venous access devices^{1–14} so that many international healthcare organizations recommend the adoption of US for many different aspects of the procedure (choice of the vein, venipuncture, tip navigation, tip location, early detection of insertion-related complications). When performing vascular access and associated procedures, the standard of care for US-guided device insertion is now endorsed and recommended by number of professional organizations (see Appendix 1). Although there has been wide recognition of its clinical benefits, there has still been slow uptake by healthcare practitioners and their respective institutions for all vascular-access-related procedures—whether it is lack of exposure, education, and skill or purely the inability to access the technology when it is needed most.

However, the successful and safe integration of this tool into clinical practice requires additional training and experience for all practitioners who plan to utilize it in their

clinical practice. This should not be a deterrent (in the use of technology) and is a relatively simple phase to implement and overcome.

Quite often, the main challenge faced by practitioners is the proper visualization of the target vessel both pre- and intra-procedurally. During the procedure, the continuous, simultaneous visualization of the vein and of the needle tip provides real-time feedback to the practitioner but may become difficult due to the narrow single plane (two-dimensional (2D)) view.^{1,3,5,6,15–22} Correct orientation of the probe and the needle is vital to achieving adequate visualization of the target vessel and the needle together,^{15–22} as well as preventing mechanical complications associated with the procedure.^{23–25} An additional difficulty

¹Global Vascular Access, LLC, Scottsdale, AZ, USA

²Department of Surgery, Catholic University Hospital “A.Gemelli”, Roma, Italy

Corresponding author:

Timothy R Spencer, Global Vascular Access, LLC, Scottsdale, AZ, 85251, USA.

Email: tim.spencer68@icloud.com

may be represented by the possibility of different options of vein visualization (transverse or “short-axis” vs longitudinal or “long axis”) and of needle visualization (out of plane vs in plane),^{17,20} so that each vein can be theoretically accessed by different techniques,¹⁹ characterized by different issues in terms of safety and applicability.^{15–22}

As there are limited number of puncture points available for placement of centrally inserted central catheters (CICCs), the potential risks of inappropriate venipuncture/cannulation should be minimized by an accurate evaluation of the state of vessel health and by a reduction of the anatomical trauma to the vessel and to the surrounding structures: this can be achieved through the adoption of a specific venous assessment and device placement protocol.²⁶

While many clinicians favor a particular vessel over another—with or without US—such criterion of “inserter familiarity” is obviously not optimal for the patient. The inserter’s ignorance of the possibilities of many different insertion sites has repeatedly been reported in clinical practice. Device placement should be based on thorough clinical assessment of vascular anatomy, type and duration of therapy, required device dwell time, laboratory findings, previous device history, and underlying comorbidities,⁸ not just on clinical guesswork or on clinician’s prejudicial preference.

The widely diffused aptitude of choosing the insertion technique on an operator-based preference rather than on a rationale choice based on the patient’s anatomy, coupled with poor training and lack of experience, often leads to procedural complications such as pneumothorax, accidental arterial puncture, local hematomas, hemothorax, and catheter malposition.^{4,23–25} Several investigators have suggested that clinician procedural volume may be an important predictor of reduced adverse events, with increased clinician experience of CICC placement shown to improve both catheter- and patient-related outcomes.²⁷ Although, procedural volume may be a protective factor only if coupled with a wise choice of appropriate methods (e.g. US guidance) and appropriate material (e.g. needle, catheter, and introducer).

There are numerous publications^{1,3–14,17–19,25–43} that recommend the use of US guidance in the support of vascular access procedures, and it is now clear that the advantage of US is not only for venipuncture. US is a powerful tool for assisting the operator in many aspects of the procedure: (1) pre-procedural US assessment of the vascular anatomy provides a rationale choice of the venous access most likely to be associated with an optimal clinical outcome; (2) real-time, US-guided puncture and cannulation of the vein reduces the risk of failure and/or damage to the surrounding structures; (3) US scan after the venipuncture allows an early/immediate detection of puncture-related complications such as pneumothorax or local hematoma; (4) US-based tip navigation verifies the proper direction of the guide wire and/or the catheter during its progression into the vasculature; (5) trans-thoracic echocardiography allows proper US-based tip location; and (6) US is also useful for detection of late

complications such as catheter-related venous thrombosis, tip migration, or fibroblastic sleeve.

In this discussion, we will focus only on the first step of this “extended” use of US during central venous access, that is, the pre-procedural assessment of central venous anatomy.

Vascular assessment prior to any intravascular device insertion is of paramount importance.^{1,4,5,8,9,11,12,14,21,22,25,26,28,44} It guides the clinician to evaluate the current state of vessel health, determining suitability of the veins, and to follow a pre-determined pathway that will lead to the best decision for the patient. The assessment phase alone in vascular access procedures highlights a number of important underlying anatomical structures, as there are frequently variances among patient groups. The success in complication reduction alone drives the importance from patient safety and improved patient and device-related outcomes, not to mention patient satisfaction and comfort.^{1,3–14,22,24,26,28,30–32,44,45}

A simple yet systematic approach to vessel assessment, originally conceptualized by the author (M.P.), is the so-called RaCeVA (Rapid Central Vein Assessment) protocol.²⁶ Initially presented at the Association for Vascular Access 23rd Scientific Meeting in 2009, this process manifested itself as a quick and highly effective process for performing vessel assessment in a compelling and methodical approach. It allows a systematic approach to exclude venous abnormalities such as thrombosis, stenosis, external compression, anatomical variations of size, and shapes; it also allows a full anatomic evaluation for optimum site selection and the best insertion approach for the patient.

As a tool, RaCeVA is designed (1) to teach the different US-guided approaches to the central veins; (2) to help the operator to scan systematically all possible venous options; and (3) to guide the operator in choosing the most appropriate vein to be accessed, on a rational and well-informed basis.

RaCeVA follows a series of seven steps, outlined in Table 1. This systematic assessment is particularly focused on the characteristics of the central veins that may be taken into consideration for venipuncture (see Table 2).

Once mastered, clinicians can perform this systematic approach with full central vascular assessment in less than 2 min. RaCeVA should always be performed bilaterally to assess for the most appropriate vessel and final exit site location, which will ultimately guide clinicians in choosing correct catheter length.

Image optimization is an important aspect of any US assessment process, as it is important to have a clear view of the anatomical structures. Onerous knobology concepts are simplified when performing RaCeVA, as the main focus is simply on gain and depth, with clear anatomical visualization, keeping the process quick and easy.

Considering the space relationship between the vein and the transducer, RaCeVA utilizes a visualization of the vessels either in short axis or in long axis (Figure 1); however, in some clinical situations, visualization in oblique axis is

Table 1. The seven steps of the Rapid Central Vein Assessment (RaCeVA).

	Transducer position	Structures to be assessed	Surrounding structures
Step 1	Mid-neck (transverse)	Internal jugular vein Carotid artery	Thyroid gland Trachea
Step 2	Base of neck (transverse)	Internal jugular vein Carotid artery Subclavian artery	Trachea Phrenic and vagus nerve
Step 3	Sternoclavicular (transverse)	Internal jugular vein Brachiocephalic vein	Pleura (mediastinum) Phrenic nerve
Step 4	Supraclavicular (longitudinal)	Subclavian vein Subclavian artery External jugular vein	Pleura (lung apex)
Step 5	Infraclavicular (transverse)	Axillary vein Axillary artery Cephalic vein	Pleura Ribs
Step 6	Infraclavicular (longitudinal)	Axillary vein Axillary artery	Pleura Ribs
Step 7	Sliding lung (longitudinal)	Pleura (anterior chest wall)	Ribs

Table 2. Criteria for choosing the vein.

1. Size of the vein (internal diameter/caliber)
2. Depth of the vein (depth of target vessel from skin surface)
3. Respiratory variations (influence of respiratory cycle on vein diameter)
4. Compression by artery (influence of arterial pulsation on vein diameter)
5. Proximity to non-venous structures which must not be damaged (pleura, nerve, and artery)
6. Exit site location—convenience/appropriateness in terms for best care and maintenance

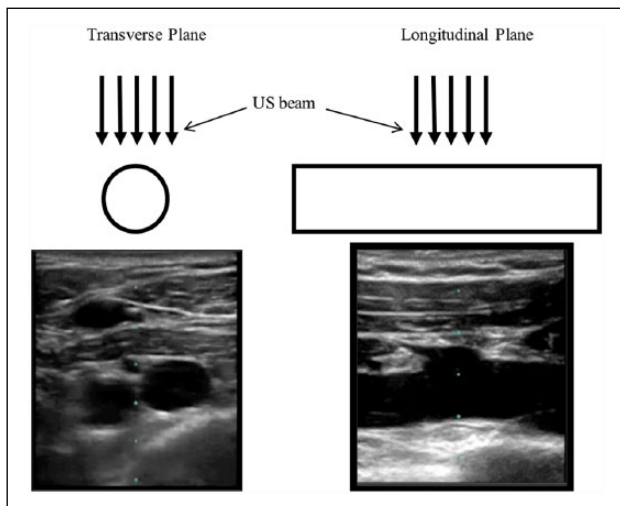


Figure 1. Transverse (short axis) and longitudinal (long axis) view of vessels.

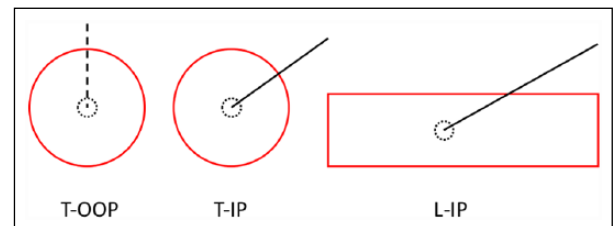


Figure 2. The three ultrasound-guided needling approaches: T-OOP=transverse (short axis)—out of plane; T-IP=transverse (short axis)—in plane; and L-IP=longitudinal (long axis)—in plane.

terms (e.g. short axis—out of plane; short axis—IP; and long axis—IP) (Figure 2).

While US assessment is a vital process pre-insertion of any centrally (or peripherally) inserted central catheter, confirming previous vascular access history of the patient is also valuable clinical information that must be acknowledged.^{1,8,9,26–28,45,50–53} These points of attention may be reliable information from patients, ensuring correct and incorrect information is clearly noted, any previous surgical procedures or localized trauma affecting vessels or potential insertion sites, previous diagnoses of thrombosis, superficial or deep vein thrombosis (DVT) whether catheter-related or not, the considerations of anticoagulant therapies, platelet count, D-dimer, and other clotting cascade considerations.⁸

sometimes useful,¹⁸ this is not applicable to RaCeVA. Please note that the terms “in-plane” (IP) and “out-of-plane” (OOP) should be used exclusively to describe the space relationship between the needle and the transducer.^{16,17,37,46–49} As a result, any US-guided venipuncture can be appropriately described using a combination of both

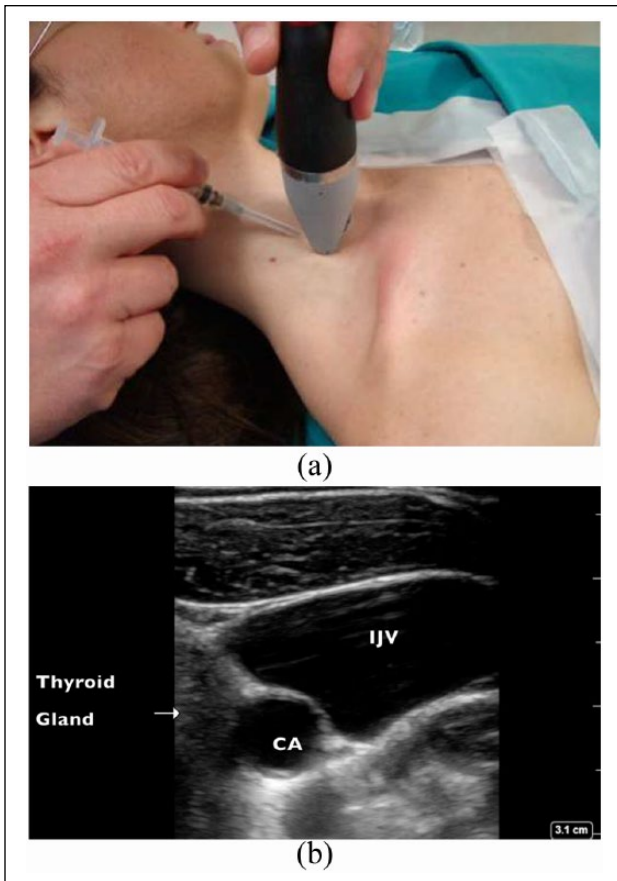


Figure 3. Step 1—probe position: transverse; probe location: mid-neck; vessel assessment (in short axis): internal jugular vein (IJV) (compressibility, size, and shape); carotid artery (CA). Typical position for IJV punctures in short axis OOP (not recommended: see text): (a) courtesy of M.P. and (b) courtesy of T.R.S.

Vessel health should be assessed in terms of patency, good compressibility, normal wall thickness, and even validation of flow assessment by color Doppler, if required. An unhealthy vessel may show poor compressibility, a hyper-echogenic reflection within vessel lumen (and/or vessel walls) as well as vessel-related thrombosis or stenosis.

Utilizing the caliber measurement tool capabilities of an US machine allows clinicians to provide greater assessment for the correct size of the vessels prior to procedures. The use of correct vessel measurement has allowed clinicians to choose an appropriate puncture site based on the caliber of the required device, so to maintain an appropriate catheter-to-vessel ratio.^{8,50,51,54} While some available US machines only have a static decal/image on the screen representing a measured vessel size, this approximate comparison for the correct catheter-to-vessel ratio is not so accurate. Also, using the depth grid/markers alone in determining the vessel diameter is a crude visual approximation only, while even small changes in vessel size can have significant effect on blood flow around the catheter, increasing thrombotic risks^{8,50,51,52,54} and estimating vessel size are not always best

when having to maintain an accurate 33%–45% catheter-to-vessel ratio,^{8,51} as even small errors have significant changes in the final calculations.^{8,45,50–53}

The assessment should also focus on the route of the target vessel as well as on its morphology. A winding or irregular pathway, the presence of bifurcations or sudden bending of the vein, or the evidence of valves may all be factors that can be associated with some difficulty in the progression of the catheter after venous cannulation. This implies that a proper US examination of the vessels should not consist in a static-only visualization, since it should include a more dynamic evaluation of the morphology of the vein and even a sort of “mapping” of the venous system around the anatomical area.

Identification of structures during RaCeVA

Step 1

The RaCeVA starts at the mid-neck region, with the transducer in a transverse position over the anterior neck, perpendicular to the skin and with a proper left/right orientation (as adopted in all imaging tomography, the left side of the probe should correspond to the left side of the display and to the right side of the patient) (Figure 3). Establishing the mid-neck region by location of the cricoid cartilage with US⁴³ is a very good starting point, as this incorporates all aspects of patient body habitus without the need for clear surface landmarks. The aim is to begin vessel assessment from below the bifurcation of the internal jugular vein (IJV). The major vessels of this area (carotid artery and IJV) can be very easily identified in short axis, even in difficult subjects, at any age (from premature newborns to aged patients). Also, this position allows an easy definition of the best value of “gain,” since it groups the reference “black” (the an-echogenic blood inside the IJV), the reference “grey” (the parenchyma of the thyroid gland), and the reference “white” (the hyper-echogenic posterior wall of the carotid artery). The IJV is assessed in terms of caliber, compressibility, its space relationship with the carotid artery, sensitivity to the respiratory variations of thoracic pressure, and possible compression due to the carotid pulsatility. Although, this is not considered an ideal location for US-guided venipuncture or exit site location.

Step 2

Sliding the transducer along the neck caudally moves from step 1 to step 2 (Figure 4). The probe is still in a transverse position, but it is located in the lower neck, in the suprasternal area. In this position, the IJV and the carotid artery are still quite easily identified in short axis. Inside the lumen of the IJV, a big transversal valve is often evident. Posteriorly to the IJV, the subclavian artery can be visualized in long axis. Such location of the subclavian artery

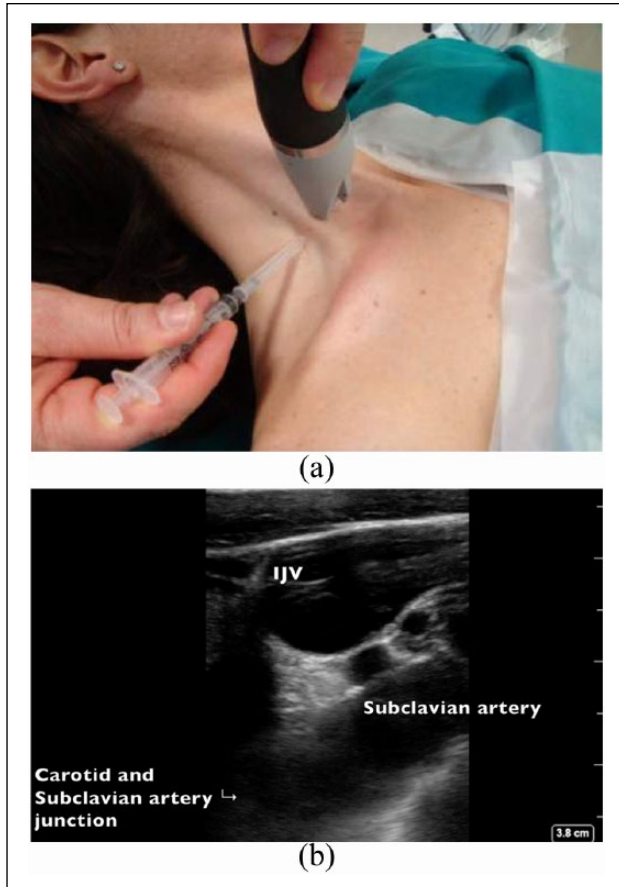


Figure 4. Step 2—probe position: transverse; probe location: lower neck (suprasternal notch); vessel assessment: lower tract of the IJV in short axis (visualization of the valve in distal IJV); subclavian artery in long axis. Ideal position for low approach IJV punctures in short axis—IP: (a) courtesy of M.P. and (b) courtesy of T.R.S.

explains the possibility of accidental arterial punctures during attempts of IJV cannulation in short axis by the OOP technique. Since the OOP does not allow proper control of the tip of the needle, the operator may puncture the IJV and pass its posterior wall, with high risk of accidental puncture of the subclavian artery.²² That is why the preferable US-guided approach to the IJV is the IP puncture in short axis, easily and safely performed in this position.^{17,18} Such technique has the additional advantage of being associated with a puncture site in the lowest portion of the neck, which implies (1) no transfixion of the sternomastoid muscle; (2) easier tunneling, if required; and (3) a more favorable insertion/exit site.¹⁶⁻²⁰

Step 3

Tilting the transducer from a perpendicular plane (step 2) to a frontal plane (step 3) allows a visualization of the structures of the superior–anterior mediastinum (Figure 5). The probe is placed parallel to the clavicle, close (and lateral) to the sternal notch. During the movement of probe

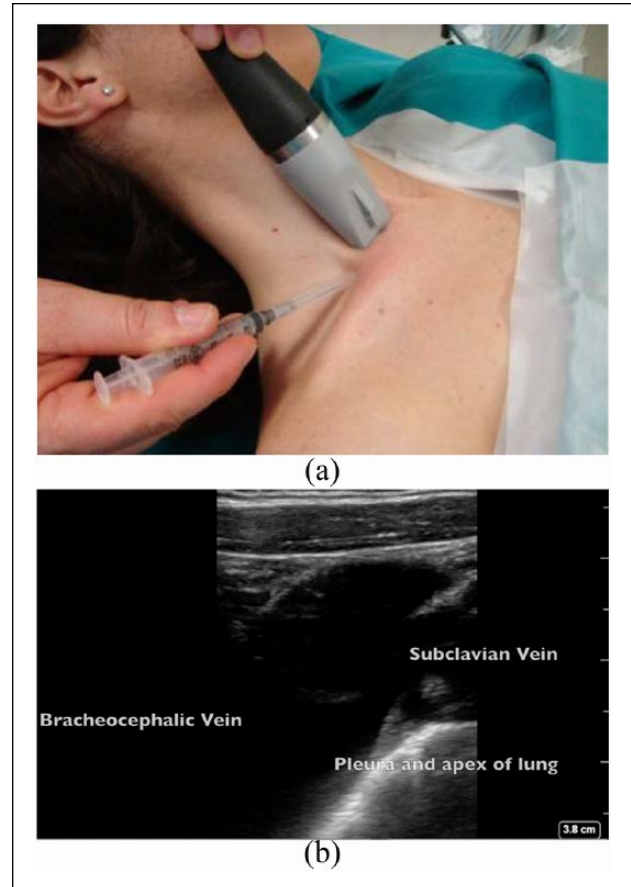


Figure 5. Step 3—probe position: frontal plane, parallel to the clavicle; probe location: above the clavicle, close to the sternal notch; vessel assessment: brachiocephalic vein (BCV) in long axis. Ideal position for “in plane” puncture of the brachiocephalic vein (long axis—IP): (a) courtesy of M.P. and (b) courtesy of T.R.S.

tilting, the operator follows the IJV while it passes over the subclavian artery, merges with the subclavian vein, and becomes the brachiocephalic vein. Due to the position of the brachiocephalic vein, the frontal plane is associated with a view of this vein in long axis: most of the length of the brachiocephalic vein can be evaluated (particularly on the right side). The mediastinal pleura is also evident, as a hyper-echogenic line lateral and parallel to the vein. In the upper portion of the vein, between the vein and the pleura, the phrenic nerve can be seen as a hypo-echogenic structure. This position is ideal for US-guided puncture and cannulation of the brachiocephalic (long axis—IP), an approach particularly recommended in neonates and children, but easily feasible also in adults.

Step 4

From the position described in step 3, the probe slides laterally in the supraclavicular area, while still in a frontal plane (Figure 6). This allows the visualization of the subclavian vein in long axis, just behind the clavicle (the supraclavicular

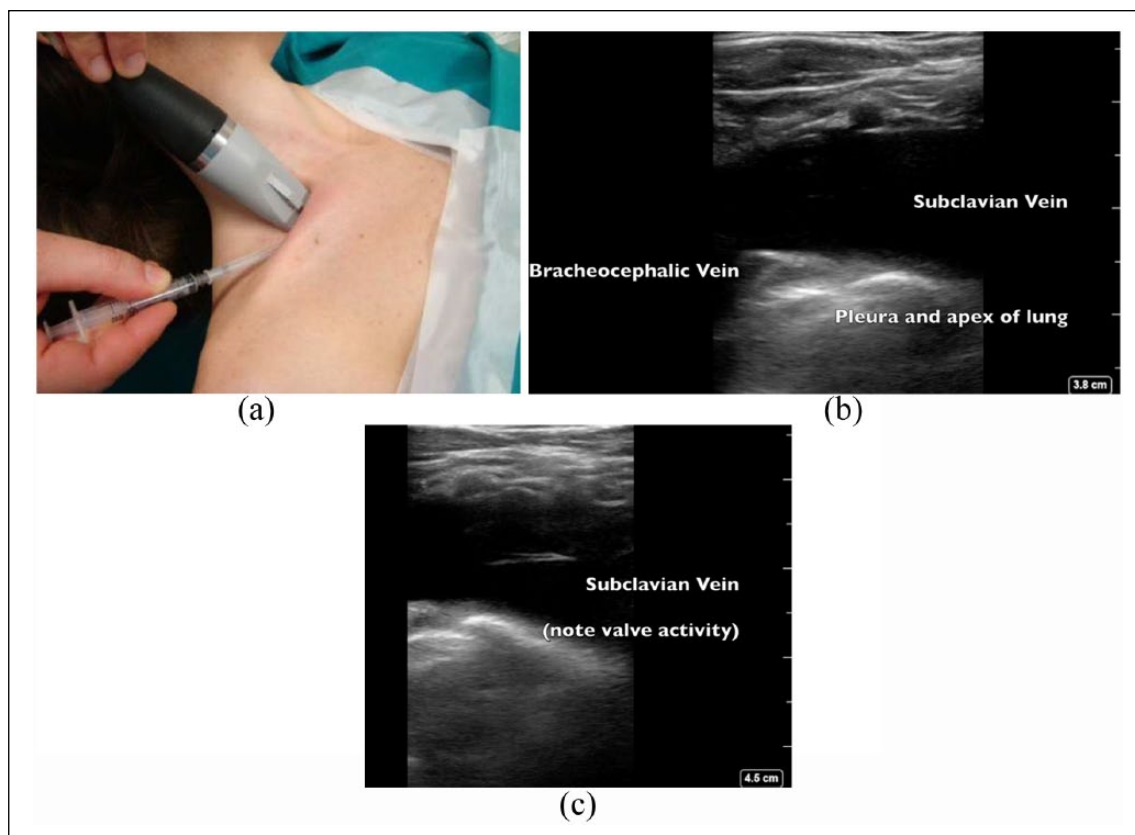


Figure 6. Step 4—probe position: from step 3, the probe slides laterally, in the supraclavicular area, still in a frontal plan; probe location: above the clavicle (supraclavicular fossa); vessel assessment: subclavian vein (SV) in long axis (visualization of “seaweed” valves); external jugular vein (EJV) in long axis; subclavian artery (SA) in short axis, more laterally. Ideal position for SV punctures in long axis IP: (a) courtesy of M.P., (b) courtesy of T.R.S., and (c) courtesy of T.R.S.

fossa). Inside the vein, some longitudinal valves are often seen, with a typical “seaweed” aspect. The final tract of the external jugular vein can often be visualized in long axis: it appears as a minor vein that runs posterior, superior, and parallel to the subclavian vein, merging medially into the brachiocephalic vein or even in the subclavian vein itself. More laterally to the subclavian vein, the subclavian artery can be visualized in short axis in its tract behind the clavicle.

This position is appropriate for US-guided puncture of the subclavian vein (long axis–IP) or of the external jugular vein (long axis–IP). The former may be associated with some potential risk of accidental pleural injury, particularly if the needle is not properly visualized during the maneuver. The external jugular vein is mostly evident in newborn and small children, and in these population of patients may represent an easy and safe approach for central venous catheterization.

Step 5

In step 5, the probe is moved to the infraclavicular area and placed parallel to the clavicle (perpendicular to the deltopectoral groove) and transverse to the thoracic wall (Figure 7). Below the lateral third of the clavicle, three

vessels can be visualized. The axillary artery is the easiest to visualize (in short axis). The axillary vein can be seen in short axis, adjacent to the artery (medially and more superficially). Both vessels lie upon the thoracic cage, with direct relationship with the ribs and with the intercostal space, but no direct contact with the pleura. Considering that, according to most anatomic textbooks, the transition between the axillary vein and the subclavian vein is located at the external margin of the first rib, it is evident that the vein that can be visualized in this step of RaCeVA is consistently the axillary vein, since the first rib is always well hidden behind the clavicle. The cephalic vein is seen in long axis, as a smaller vessel that passes over the artery and merges into the axillary vein.

In this position, the axillary vein (visualized in short axis) can be accessed by an OOP technique. Such approach has no risk of arterial puncture (since the transverse position of the probe implies a “panoramic view” of both vessels), but it may be associated with a minimal but significant risk of pleural damage if the tip of the needle accidentally passes both the posterior wall of the vein and the intercostal space. The cephalic vein can also be punctured by US guidance, if it is not too small.

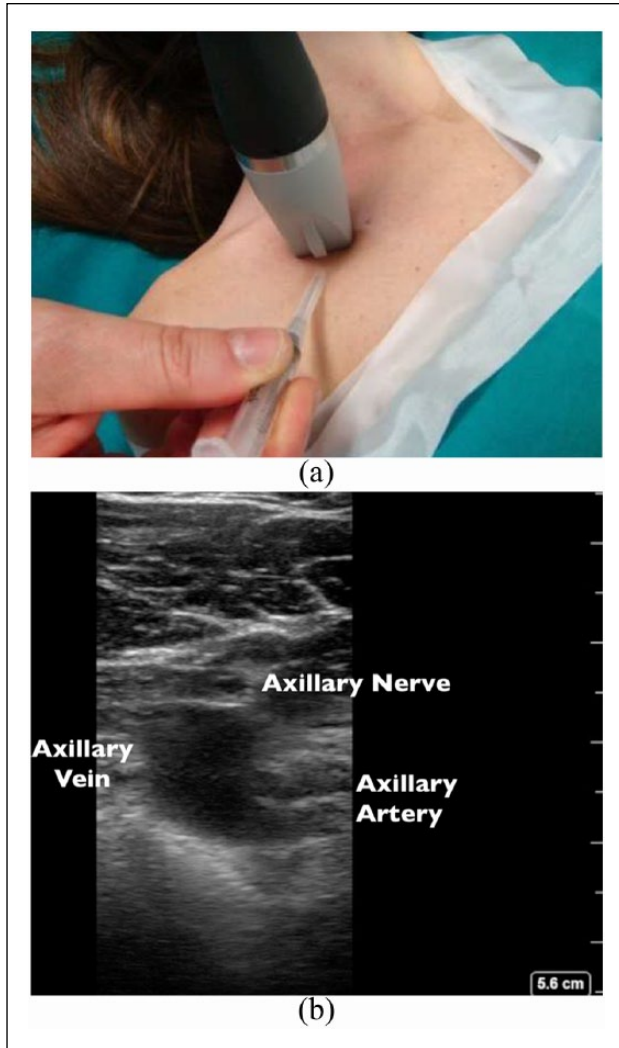


Figure 7. Step 5—probe position: perpendicular to the deltopectoral groove (roughly parallel to the clavicle), transverse to the thoracic wall; probe location: below the lateral third of the clavicle; vessel assessment: axillary vein (AxV) in short axis; axillary artery (AxA) in short axis; cephalic vein (CV) in long axis. Ideal position for “out of plane” punctures of the axillary vein (short axis–OOP): (a) courtesy of M.P. and (b) courtesy of T.R.S.

Step 6

From step 5, if the probe is gently rotated on its own axis (either clockwise or counter-clockwise), the operator obtains step 6 (Figure 8). The transducer is still placed below the clavicle, but it is now longitudinal and perpendicular to the thoracic wall, more or less parallel to the deltopectoral groove. Due to the 90° rotation, the axillary vein and the axillary artery can now be seen in long axis, often closely parallel to each other. In this longitudinal view, the relationship between the vessels and the underlying structures (ribs and intercostal space) is more evident. In this position, the axillary vein can be punctured by US guidance in long axis, with an IP technique. The IP approach allows

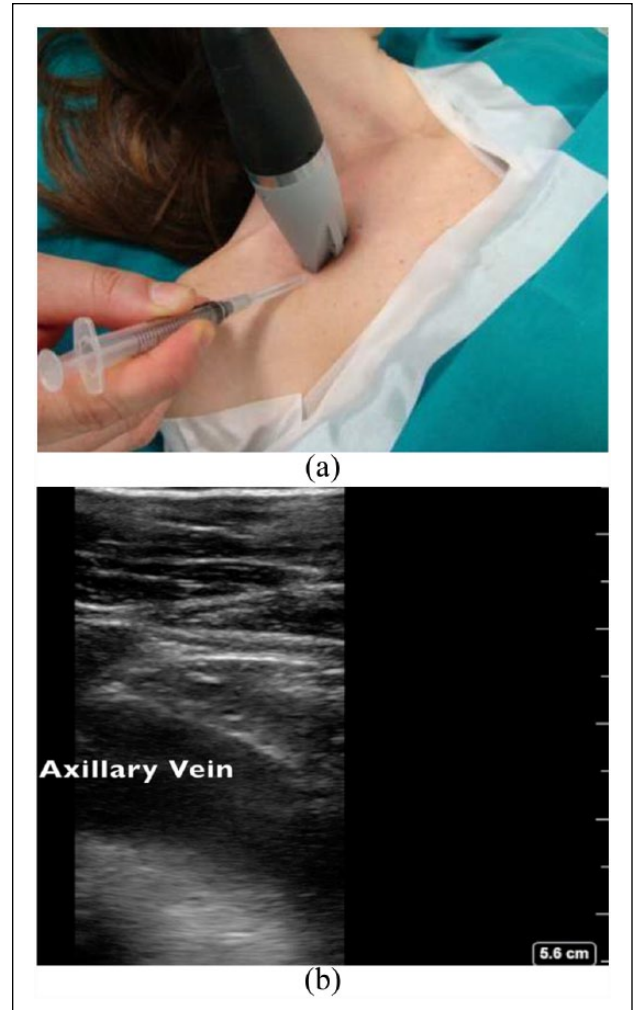


Figure 8. Step 6—probe position: perpendicular to the clavicle (parallel to the deltopectoral groove), longitudinal to the thoracic wall; probe location: below the lateral 1/3 of the clavicle; vessel assessment: axillary vein (AV) in long axis; axillary artery in long axis; cephalic vein (CV) in long axis. Ideal position for “in plane” punctures of the axillary vein (long axis–IP): (a) courtesy of M.P. and (b) courtesy of T.R.S.

to nullify the risk of accidental transfixion of the intercostal space and subsequent pleural injury; still, a lack of precision in directing the needle tip may be associated with a minimal but significant risk of accidental arterial puncture.

Step 7

Assessment of pleural function in the pre-insertion phase offers many clinical advantages, namely, providing an accurate baseline assessment prior to the insertion of a CICC (Figure 9). Intercostal spaces on the anterior chest at the midclavicular line should be assessed bilaterally. The visceral–parietal pleura interface is assessed in both B-mode (2D) and M-mode (one-dimensional (1D)), to demonstrate the “lung sliding” sign (in B-mode; Supplementary Video 1) and “seashore or sandy beach”

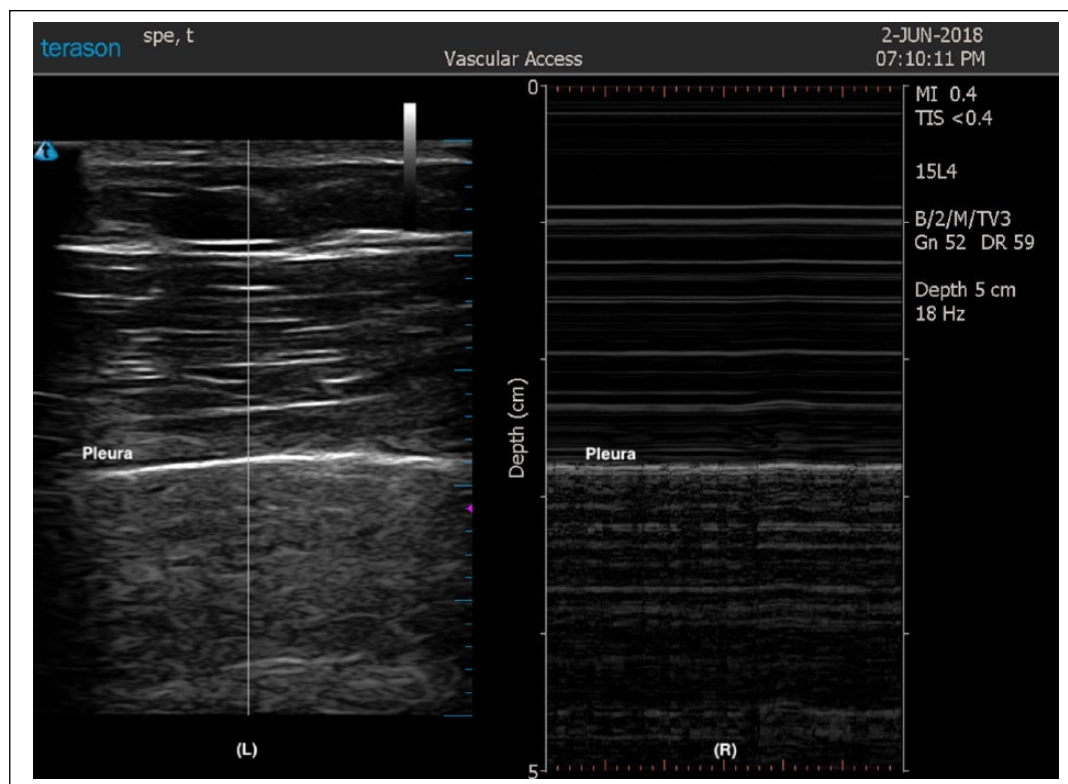


Figure 9. Step 7—sliding lung assessment—this is performed both in the assessment phase and in the post-insertion phase for exclusion of pneumothorax. Intercostal spaces on the anterior chest (1 through 3) at the midclavicular line are assessed. The visceral–parietal pleural interface is evaluated in both B-mode and M-mode to demonstrate lung sliding and seashore sign, respectively. Lung ultrasound demonstrating lung sliding of the visceral–parietal pleural interface in B-mode (L) and seashore sign in M-mode (R): image courtesy of T.R.S.

sign (in M-mode). Positioning of the probe not only familiarizes the clinician with the underlying landmarks but also puts them in an advantageous position should needle decompression be required because of accidental pleural puncture. This starting position of the third intercostal space, at the midclavicular line, is also the internationally recognized site for acute pleural decompression for symptomatic pneumothorax or tension pneumothorax. After placement of a CICC in either the IJV, brachiocephalic, subclavian, or axillary vein, an assessment for pneumothorax should always be performed and compared to the original baseline assessment.

The evidence of lung sliding^{36–43} essentially rules out pneumothorax (sensitivity, 100%); however, its absence does not confirm it (specificity, 91%).⁵⁵ A false-positive result may be avoided by knowing the “state” of the pleural line before central venous catheter placement, so that prior assessment before venipuncture is recommended.²⁹ For the purpose of ruling out pneumothorax, the following criteria should be met:

1. Lung sliding visualized in B-mode.
2. Seashore (or sandy beach) sign visualized in M-mode.
3. Presence of B-lines.

A recent prospective non-inferiority study⁴² confirmed 100% accuracy in the use of US to demonstrate that point of care US can facilitate the clinical use of CICCs by expeditious exclusion of CICC-related complications, particularly pneumothorax and accurate position of the catheter tip. The clinical implications of this study highlight the benefits from reduction of patient exposure to radiation, improved clinical care, and potential cost savings.⁴²

Summary

US-guided vascular assessment should always be considered the first choice to provide for vascular access to central venous and arterial vessels, as well as in difficult peripheral venous cannulation situations.

The RaCeVA is a protocol designed for an easy, rapid, and systematic assessment of the six central veins that can be theoretically punctured and cannulated by US in the supra/infraclavicular area: IJV, external jugular vein, brachiocephalic vein, and subclavian vein (in the supraclavicular area); axillary vein and cephalic vein (in the infraclavicular area). Also, the RaCeVA allows to visualize the surrounding structures that could be accidentally injured during venous catheterization (carotid artery, subclavian artery, axillary artery, pleura, and phrenic and vagus nerves). This RaCeVA

has many advantages: it takes only 30–40 s for each side; it is easy to teach, easy to learn, and it is a useful guide for a rational choice of the central vein to be accessed, in terms of patient safety and cost-effectiveness, since it helps the operator to choose the most favorable puncture site and the optimal insertion site, with an overall improvement of the clinical outcomes and patient satisfaction.

Utilization of the RaCeVA protocol (See Figure 10 for RaCeVA overview) throughout both pre- and post-device insertion stages offers multiple advantages; “before” (to define the anatomy and the best target vessel), “during” (with real-time techniques of US-guided venipuncture: short axis–IP, short axis–OOP, long axis–IP); and “after” cannulation (to detect or rule out complications such as pneumothorax, malpositions, and local hematoma). Optimal training is mandatory, through formal programs and hands-on sessions that imply using “vascular simulation phantoms”—the latter being especially important for practitioners to perform repeated US-guided vascular cannulations without posing serious risks for patients and ultimately successfully transferring this practice to patients.

Rapid Central Vein Assessment:

- It takes only 20–30 s for each side
- It is easy to teach, easy to learn
- It is a useful guide for a rational choice of the central vein to be accessed, in terms of:
 - Patient’s safety
 - Cost-effectiveness
 - Improved performance of central venous catheterization

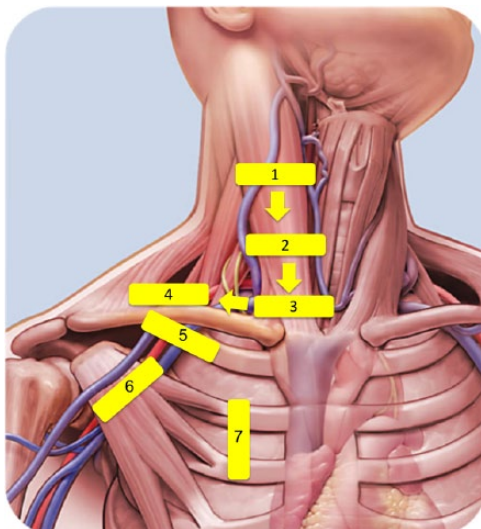


Figure 10. Overview of RaCeVA steps highlighting ultrasound transducer scanning points: courtesy of M.P./T.R.S.

Declaration of conflicting interests

The author(s) declared no potential conflicts of interest with respect to the research, authorship, and/or publication of this article.

Funding

The author(s) received no financial support for the research, authorship, and/or publication of this article.

References

1. Lamperti M, Bodenham AR, Pittiruti M, et al. International evidence-based recommendations on ultrasound-guided vascular access. *Intensive Care Med* 2012; 38(7): 1105–1117.
2. Zieleskiewicz L, Muller L, Lakhil K, et al. Point-of-care ultrasound in intensive care units: assessment of 1073 procedures in a multicentric, prospective, observational study. *Intensive Care Med* 2015; 41(9): 1638–1647.
3. Brass P, Hellmich M, Kolodziej L, et al. Ultrasound guidance versus anatomical landmarks for internal jugular vein catheterization. *Cochrane Database Syst Rev* 2015; 1: CD006962.
4. Pittiruti M, Hamilton H, Biffi R, et al. ESPEN guidelines on parenteral nutrition: central venous catheters (access, care, diagnosis and therapy of complications). *Clin Nutr* 2009; 28(4): 365–377.
5. Bouaziz H, Zetlaoui PJ, Pierre S, et al. Guidelines on the use of ultrasound guidance for vascular access. *Anaesth Crit Care Pain Med* 2015; 34(1): 65–69.
6. Wu SY, Ling Q, Cao LH, et al. Real-time two-dimensional ultrasound guidance for central venous cannulation: a meta-analysis. *Anesthesiology* 2013; 118(2): 361–375.
7. Bodenham A, Babu S, Bennett J, et al. Association of Anaesthetists of Great Britain and Ireland: safe vascular access 2016. *Anaesthesia* 2016; 71(5): 573–585.
8. Gorski L, Hadaway L, Hagle M, et al. Infusion therapy standards of practice. *J Infus Nurs* 2016; 39(1S): S1–S159.
9. Moureau N, Lamperti M, Kelly LJ, et al. Evidence-based consensus on the insertion of central venous access devices: definition of minimal requirements for training. *Br J Anaesth* 2013; 110(3): 347–356.
10. Randolph AG, Cook DJ, Gonzales CA, et al. Ultrasound guidance for placement of central venous catheters: a meta-analysis of the literature. *Crit Care Med* 1996; 24(12): 2053–2058.
11. Troianos CA, Hartman GS, Glas KE, et al. Special articles: guidelines for performing ultrasound guided vascular cannulation: recommendations of the American Society of Echocardiography and the Society of Cardiovascular Anesthesiologists. *Anesth Analg* 2012; 114(1): 46–72.
12. AIUM practice guideline for the use of ultrasound to guide vascular access procedures. *J Ultrasound Med* 2013; 32: 191–215.
13. Lalu MM, Fayad A, Ahmed O, et al. Ultrasound-guided subclavian vein catheterization: a systematic review and meta-analysis. *Crit Care Med* 2015; 43(7): 1498–1507.
14. Saugel B, Scheeren TW and Teboul JL. Ultrasound-guided central venous catheter placement: a structured review and recommendations for clinical practice. *Crit Care* 2017; 21(1): 225.
15. Resnick JR, Cydulka R and Jones R. Comparison of two transducers for ultrasound-guided vascular access in long axis. *J Emerg Med* 2007; 33(3): 273–276.
16. Stone MB, Moon C, Sutijono D, et al. Needle tip visualization during ultrasound-guided vascular access: short-axis vs long-axis approach. *Am J Emerg Med* 2010; 28(3): 343–347.

17. Chittoodan S, Breen DD, O'Donnell B, et al. Long versus short axis ultrasound guided approach for internal jugular vein cannulation: a prospective randomised controlled trial. *Med Ultrason* 2011; 13(1): 21–25, <https://medultrason.ro/medultrason/index.php/medultrason/article/view/691>
18. DiLisio R and Mitnacht AJ. The “medial-oblique” approach to ultrasound-guided central venous cannulation: maximize the view, minimize the risk. *J Cardiothorac Vasc Anesth* 2012; 26(6): 982–984.
19. Vogel JA, Haukoos JS, Erickson CL, et al. Is long-axis view superior to short-axis view in ultrasound-guided central venous catheterization? *Crit Care Med* 2015; 43(4): 832–839.
20. Rossi UG, Rigamonti P, Tichà V, et al. Percutaneous ultrasound-guided central venous catheters: the lateral in-plane technique for internal jugular vein access. *J Vasc Access* 2014; 15(1): 56–60.
21. Schofer JM, Nomura JT, Bauman MJ, et al. The “Ski Lift”: a technique to maximize needle visualization with the long-axis approach for ultrasound-guided vascular access. *Acad Emerg Med* 2010; 17: e83–e84.
22. Blaivas M and Adhikari S. An unseen danger: frequency of posterior vessel wall penetration by needles during attempts to place internal jugular vein central catheters using ultrasound guidance. *Crit Care Med* 2009; 37(8): 2345–2349.
23. Biasucci DG, La Greca A, Scoppettuolo G, et al. Ultrasound-guided central venous catheterization: it is high time to use a correct terminology. *Crit Care Med* 2015; 43(9): e394–e396.
24. Bowdle A. Vascular complications of central venous catheter placement: evidence-based methods for prevention and treatment. *J Cardiothorac Vasc Anesth* 2014; 28(2): 358–368.
25. Galloway S and Bodenham A. Ultrasound imaging of the axillary vein—anatomical basis for central venous access. *Br J Anaesth* 2003; 90(5): 589–595.
26. Pittiruti M and LaGreca A. How to choose the most appropriate ultrasound-guided approach for central line insertion: introducing the rapid central venous assessment protocol. In: Lumb P and Karakitsos D (eds) *Critical care ultrasound*. Philadelphia, PA: Saunders, 2014, pp. 76–79.
27. Alexandrou E, Spencer TR, Frost SA, et al. Central venous catheter placement by advanced practice nurses demonstrates low procedural complication and infection rates—a report from 13 years of service. *Crit Care Med* 2014; 42(3): 536–543.
28. Griswold-Theodorson S, Hannan H, Handly N, et al. Improving patient safety with ultrasonography guidance during internal jugular central venous catheter placement by novice practitioners. *Simul Healthc* 2009; 4(4): 212–216.
29. Saul T, Doctor M, Kaban NL, et al. The ultrasound-only central venous catheter placement and confirmation procedure. *J Ultrasound Med* 2015; 34(7): 1301–1306.
30. Pittiruti M, LaGreca A, Scoppettuolo G, et al. Ultrasound-guided vs ultrasound-assisted central venous catheterization. *Crit Care* 2007; 11(2): P158.
31. Blanco P and Volpicelli G. Common pitfalls in point-of-care ultrasound: a practical guide for emergency and critical care physicians. *Crit Ultrasound J* 2016; 8(1): 15.
32. Blanco P. Ultrasound-guided vascular cannulation in critical care patients: a practical review. *Med Intensiva* 2016; 40(9): 560–571.
33. Borja AR and Hinshaw JR. A safe way to perform infraclavicular subclavian vein catheterization. *Surg Gynecol Obstet* 1970; 130(4): 673–676.
34. Sharma A, Bodenham AR and Mallick A. Ultrasound-guided infraclavicular axillary vein cannulation for central venous access. *Br J Anaesth* 2004; 93(2): 188–192.
35. O’Leary R, Ahmed SM, McLure H, et al. Ultrasound-guided infraclavicular axillary vein cannulation: a useful alternative to the internal jugular vein. *Br J Anaesth* 2012; 109(5): 762–768.
36. Maury E, Guglielminotti J, Alzieu M, et al. Ultrasonic examination: an alternative to chest radiography after central venous catheter insertion? *Am J Respir Crit Care Med* 2001; 164(3): 403–405.
37. Vezzani A, Brusasco C, Palermo S, et al. Ultrasound localization of central vein catheter and detection of postprocedural pneumothorax: an alternative to chest radiography. *Crit Care Med* 2010; 38(2): 533–538.
38. Bedel J, Vallée F, Mari A, et al. Guidewire localization by transthoracic echocardiography during central venous catheter insertion: a periprocedural method to evaluate catheter placement. *Intensive Care Med* 2013; 39(11): 1932–1937.
39. La Greca A, Biasucci DG, Emoli A, et al. Improving the “global use” of ultrasound for central venous access: a new supraclavicular scan by microconvex probe. *Crit Ultrasound J* 2014; 6(S2): A11.
40. Kim SC, Heinze I, Schmiedel A, et al. Ultrasound confirmation of central venous catheter position via a right supraclavicular fossa view using a microconvex probe: an observational pilot study. *Eur J Anaesthesiol* 2015; 32(1): 29–36.
41. Biasucci DG, La Greca A, Scoppettuolo G, et al. What’s really new in the field of vascular access? Towards a global use of ultrasound. *Intensive Care Med* 2015; 41(4): 731–733.
42. Amir R, Knio ZO, Mahmood F, et al. Ultrasound as a screening tool for central venous catheter positioning and exclusion of pneumothorax. *Crit Care Med* 2017; 45(7): 1192–1198.
43. Bair AE and Chima R. The inaccuracy of using landmark techniques for cricothyroid membrane identification: a comparison of three techniques. *Acad Emerg Med* 2015; 22(8): 908–914.
44. Pittiruti M. Ultrasound guided central vascular access in neonates, infants and children. *Curr Drug Targets* 2012; 13(7): 961–969.
45. Chopra V, Kuhn L, Ratz D, et al. Vascular access specialist training, experience, and practice in the United States: results from the national PICC1 survey. *J Infus Nurs* 2017; 40(1): 15–25.
46. Blaivas M, Brannam L and Fernandez E. Short-axis versus long-axis approaches for teaching ultrasound-guided vascular access on a new inanimate model. *Acad Emerg Med* 2003; 10(12): 1307–1311.
47. Sommerkamp SK, Romaniuk VM, Witting MD, et al. A comparison of longitudinal and transverse approaches to ultrasound-guided axillary vein cannulation. *Am J Emerg Med* 2013; 31(3): 478–481.
48. Vezzani A, Manca T, Brusasco C, et al. A randomized clinical trial of ultrasound-guided infra-clavicular cannulation of the subclavian vein in cardiac surgical patients: short-axis versus long-axis approach. *Intensive Care Med* 2017; 43(11): 1594–1601.

49. Popovich MJ. Ultrasound-guided vascular access in critical care: can a choice of real-time imaging axis view overcome the “curse of dimensionality”? *Crit Care Med* 2015; 43(4): 920–921.
50. Sharp R, Cummings M, Fielder A, et al. The catheter to vein ratio and rates of symptomatic venous thromboembolism in patients with a peripherally inserted central catheter (PICC): a prospective cohort study. *Int J Nurs Stud* 2015; 52(3): 677–685.
51. Spencer TR and Mahoney KJ. Reducing catheter-related thrombosis using a risk reduction tool centered on catheter to vessel ratio. *J Thromb Thrombolysis* 2017; 44(4): 427–434.
52. Itkin M, Mondschein JI, Stavropoulos SW, et al. Peripherally inserted central catheter thrombosis—reverse tapered versus nontapered catheters: a randomized controlled study. *J Vasc Interv Radiol* 2014; 25(1): 85–91.
53. Moureau N and Chopra V. Indications for peripheral, mid-line and central catheters: summary of the MAGIC recommendations. *Br J Nurs* 2016; 25(8): S15–S24.
54. Nifong TP and McDevitt TJ. The effect of catheter to vein ratio on blood flow rates in a simulated model of peripherally inserted central venous catheters. *Chest* 2011; 140(1): 48–53.
55. Lichtenstein D, Meziere G, Biderman P, et al. The comet-tail artifact: an ultrasound sign ruling out pneumothorax. *Intensive Care Med* 1999; 25(4): 383–388.

Appendix I

International organizations endorsing and/or recommending ultrasound-guided device insertion

- Agency for Healthcare Research and Quality (AHRQ)
- American Academy of Physician Assistants (AAPA)
- American Association of Critical Care Nurses (AACN)
- American Association of Nurse Anesthetists (AANA)
- American Cardiology Association (ACA)
- American College of Emergency Physicians (ACEP)
- American Institute of Ultrasound in Medicine (AIUM)
- American Society of Anesthesiologists (ASA)
- American Society of Diagnostic and Interventional Nephrology (ASDIN)
- American Society of Echocardiography (ASE)
- Association for Professionals in Infection Control and Epidemiology (APIC)
- Association for Vascular Access (AVA)
- Association of Anaesthetists of Great Britain and Ireland (AAGBI)
- Association of Physician Assistants in Cardiovascular Surgery (APACS)
- Australian and New Zealand Intensive Care Society (ANZICS)
- Australasian Society for Ultrasound in Medicine (ASUM)
- Canadian Vascular Access Association (CVAA)
- Cancer Nurses Society of Australia (CNSA)
- Centers for Disease Control and Prevention (CDC)
- European Society for Parenteral and Enteral Nutrition (ESPEN)
- Infusion Nurses Society (INS)
- Institute for Healthcare Improvement (IHI)
- Intravenous Nursing New Zealand Incorporated Society (IVNNZ)
- Italian Group of Central Venous Access (GAVeCeLT)
- National Institute for Health and Care Excellence (NICE)
- National Kidney Foundation (NKF)
- Oncology Nursing Society (ONS)
- Registered Nurses’ Association of Ontario (RNAO)
- The Royal College of Anaesthetists (RCA)
- Royal College of Nursing (RCN)
- The Joint Commission (TJC)
- Society for Healthcare Epidemiology of America (SHEA)
- World Interactive Network Focused on Critical Ultrasound (WINFOCUS)
- World Congress on Vascular Access (WoCoVA)